

examine the efficacy of antidepressants in pain management on veterans in order to provide an alternative to opioids.

Methods Throughout this work, with the use of data collection and data analysis, enough evidence was found of the efficacy of antidepressants and the need for proper guidelines to transition from the drugs currently used for pain management to antidepressants.

Results In general, the use of tricyclic antidepressants (TCAs) for the management of chronic pain has proven to have one of the most significant antihyperalgesic effects. However, SSRIs such as sertraline and fluoxetine have also demonstrated benefits in treating PTSD, fibromyalgia and chronic tension headaches in females. In conclusion, the usage of antidepressants makes it possible to achieve proper treatment of comorbid conditions while also helping with the diminishing of opioid usage.

Conclusions This study underscores the importance of addressing the opioid crisis among veterans by exploring the effectiveness of antidepressants in pain management. These findings support the use of tricyclic antidepressants and SSRIs as a viable alternative to opioids, providing potential relief for chronic pain and comorbid conditions. In the same way this opens opportunities to develop new guidelines for first line treatments in patients with chronic pain.

#34931 PERIPHERAL NERVE BLOCKS FOR THE LUMBAR RADICULOPATHY; A 1 YEAR FOLLOW UP STUDY

Sumedha Suresh Kumar, Praveen Talawar*, Ajit Kumar. *Anaesthesiology, All India Institute of Medical Sciences, Rishikesh, Rishikesh, India*

10.1136/rapm-2023-ESRA.359

Please confirm that an ethics committee approval has been applied for or granted: Yes: I'm uploading the Ethics Committee Approval as a PDF file with this abstract submission

Application for ESRA Abstract Prizes: I don't wish to apply for the ESRA Prizes

Background and Aims Low back pain due to lumbar radiculopathy is the cause of significant disability. Epidural steroid injections with or without local anaesthetic are often prescribed to patients who are not responding to conservative management. Epidural injections may carry the attended risk of neurological injuries. We hypothesized that the nociceptor fibres being pseudo – unipolar in nature, with both ends behaving functionally the same. The peripheral nerve blocks administered distally should be as effective in providing pain relief.

Methods The thirty-four patients who had been recruited in the single-arm study were followed up at 6 months and 12 months post the intervention and the outcomes were noted. They had been administered peripheral nerve blocks at ankle level with 4ml of 0.25% bupivacaine and 40mg of triamcinolone. Outcomes measured: The outcomes measured at 6 and 12 months after the intervention were the pain intensity (Numerical Rating Scale), the Global Perceived Effect, employment status, and analgesic intake.

Results Out of 34 patients, 4 had dropped out at 6 months and 12 at 12 months. Statistical analysis of the data showed a significant decrease in pain intensity ($p < 0.001$). There was also a significant improvement in both the employment status and the analgesic intake and no additional side effects were reported by any of the patients.

Conclusions This present study shows that peripheral nerve blocks are effective in the management of pain in patients with lumbosacral radiculopathy even in the long term (1 year) with no significant adverse effects.

Attachment 72429883_d5d6_4353_814d_1ebc4cb72bdf.pdf

#36242 INTEGRATIVE PAIN CARE: SYMBIOSIS BETWEEN CHRONIC PAIN UNIT AND PALLIATIVE CARE IS THE KEY

¹Dulce Pereira*, ¹Joana Pinto, ¹Maria do Céu Loureiro, ¹Elena Segura, ²Marta Mós, ¹Alexandra Guedes. ¹Anesthesiology, Centro Hospitalar Tondela – Viseu, Viseu, Portugal; ²Palliative Care Unit, Centro Hospitalar Tondela – Viseu, Viseu, Portugal

10.1136/rapm-2023-ESRA.360

Please confirm that an ethics committee approval has been applied for or granted: Not relevant (see information at the bottom of this page)

Background and Aims Inpatient and after discharge palliative care is essential to improve quality of end-of-life. Critical limb ischemia is associated with an excruciating pain. We describe the successful in-hospital and after discharge use of perineural sciatic nerve catheter to control refractory ischemic pain.

Methods Data was collected through consultation of clinical records.

Results

Case report A 77-year-old female was admitted with decompensated heart failure (NYHA class IV) and respiratory failure requiring non-invasive ventilation. Medical history included atrial fibrillation, severe aortic stenosis, arterial hypertension, obesity, poorly controlled diabetes mellitus and bilateral chronic lower limb ischemia. Physical examination revealed necrosis of the right foot and ulcerations on the left one. Surgical treatment was refused, and conservative/confort measures were adopted. Despite morphine intravenous infusion, severe pain at rest and during wound dressing was referred. Chronic pain unit consultation was required, and continuous sciatic popliteal nerve block was proposed. Immediate relief was reported after the first bolus and a DIB with ropivacaine was initiated. Given the bad clinical prognosis and patient's desire for home discharge, patient went home with perineural popliteal DIB of ropivacaine 0.1% 5mL/h (replaced every 3 days at the chronic pain unit) and fixed 5mg oral morphine including before wound dressing, performed by the primary healthcare team. Excellent pain efficacy (EN 2/10) and high level of patient and family's satisfaction were reported.

Conclusions Home-based palliative care decreases readmissions and health care utilisation. Locoregional analgesia may be an effective tool establishing the bridge between acute and home-based palliative care for management of chronic pain at end-of-life patients.

#36417 POSTERIOR REVERSIBLE ENCEPHALOPATHY SYNDROME AFTER OXYGEN-OZONE THERAPY FOR CERVICAL AND LOW BACK PAIN: A CASE REPORT

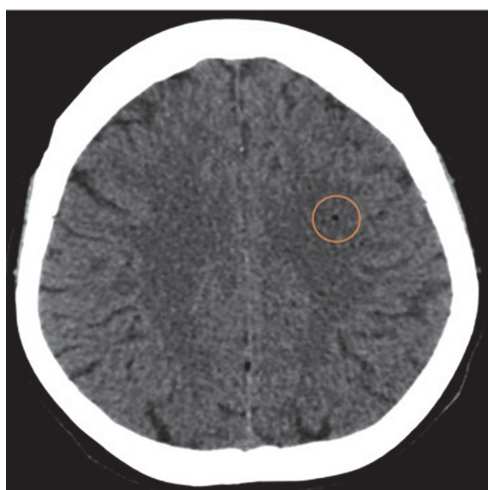
Marta Rodriguez Cornet*, Eleuteri Vidal Agustí, Jean Louis Camille Clave, Marina Alcobero Gonzalez, Mónica Pérez-Poquet, Marc Bausili Ribera. *Anesthesiology, Hospital Universitari Mútua Terrassa, Terrassa, Spain*

10.1136/rapm-2023-ESRA.361

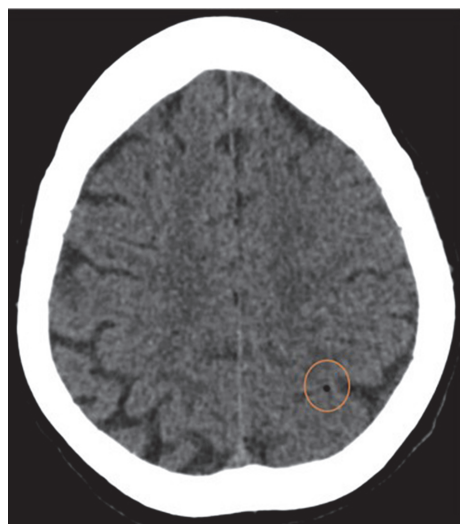
Please confirm that an ethics committee approval has been applied for or granted: Yes: I'm uploading the Ethics Committee Approval as a PDF file with this abstract submission

Background and Aims Back pain is a very common pathology in Chronic Pain Units, often induced by lumbar disc herniation. Different therapeutic interventions have been studied, being conservative measures first-line treatment. Oxygen-ozone injections are becoming more common as an alternative therapy but its efficacy in terms of pain relief and functional improvement is uncertain. Even though it is considered a minimally invasive technique, potential complications such as hematoma, local infections or nerve irritation, have been described.

Methods We present a case of a patient who suffered a posterior reversible encephalopathy syndrome (PRES) secondary to a subarachnoid embolism after oxygen-ozone injections, a side effect non-previously reported in the literature.



Abstract #36417 Figure 1 CT caption showing air bubbles in subarachnoid sulci of the left frontal convexity with subcutaneous emphysema



Abstract #36417 Figure 2 CT captions showing air bubbles in subarachnoid sulci of the parietal lateral convexity with subcutaneous emphysema

Results 83-year-old woman, with general arthrosis and chronic back pain secondary to herniated disc, electively submitted to oxygen-ozone intradiscal injection in an outpatient clinic. Immediately after the injection, she suffered a sudden decrease of consciousness and was transferred to our hospital. She presented a Glasgow Score of 8, global aphasia, right oculocephalic deviation, right upper extremity claudication and bilateral babinski sign. An AngioCT scan showed two air bubbles in subarachnoid sulci of the left frontal and parietal lateral convexity with subcutaneous emphysema. She was intubated, transferred to ICU and received two hours of hyperbaric therapy. Magnetic resonance showed probable PRES secondary to oxygen-ozone encephalic embolism. Afterwards, she could be extubated with no neurological sequelae.

Conclusions Oxygen-ozone injections as intradiscal therapies, have multiple associated complications that must be taken into account when assessing risks and benefits. Further studies are needed to evaluate outcomes and associated complications.

Attachment Consent.pdf

#36057

INTRA-ARTICULAR COMBINATION OF FENTANYL, DEXAMETHASONE, CLONIDINE, ROPIVACAINE AND DEXTROSE AGAINST PAIN DUE TO KNEE OSTEOARTHRITIS: A CASE REPORT

¹Theofilos Tsoleridis*, ²Alexandros Pittas. ¹Anesthesia and Pain Unit, General Hospital of Rhodes, Greece, Rhodes, Greece; ²Orthopedic Clinic, General Hospital of Rhodes, Greece, Rhodes, Greece

10.1136/rapm-2023-ESRA.362

Please confirm that an ethics committee approval has been applied for or granted: Not relevant (see information at the bottom of this page)

Application for ESRA Abstract Prizes: I don't wish to apply for the ESRA Prizes

Background and Aims The purpose of this study is to describe a patient with knee osteoarthritis (KOA), where both pharmacological and non-pharmacological regimens proved inadequate and could not undergo surgery for total joint replacement (TJR). At this dead-end, intra-articular (IA) combination of various agents was applied aiming for a multifactorial approach. Currently there is no literature regarding similar treatment.

Methods A 81 years old female with KOA was treated gradually with paracetamol, diclofenac and later with tramadol/dexketoprofane but reported minimal improvement of her condition after two months. After IA injections of hyaluronic acid initially and platelet-rich plasma later seemed to offer no results, an IA combination of fentanyl 50mcg, dexamethasone 8mg, clonidine 150mcg, ropivacaine 7.5% 5ml dextrose 30% 5ml and natural saline 0.9% 5ml was applied after the patient's informed consent.

Results The treatment led to pain absence that lasted for about two years.

Conclusions As the patient was not eligible for IA Stem Cells or TJR and was non responsive to both pharmacological and invasive treatments, the resulting dead-end urged for improvement. The multifactorial approach seems to offer satisfactory and encouraging results as the quality of life improvement